

INTRODUCTION

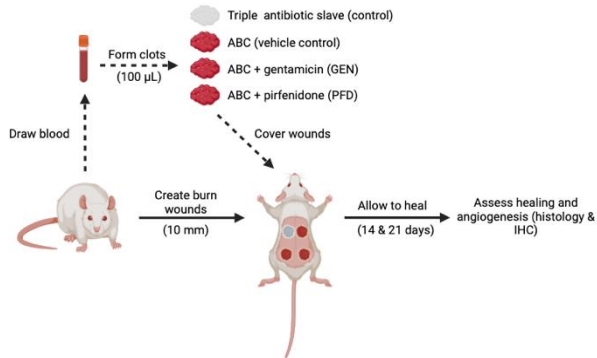
Deep, partial-thickness burn wounds

- Deep, partial-thickness burn wounds can result in debilitating injuries with extensive hypertrophic scarring and contractures
- Wound dressings are a critical aspect of care;
- Some biologic dressings exist (e.g., EpiBurn, PermaDerm, ReCell, amniotic membranes).
- RCTs have yet to identify an optimal dressing for partial-thickness burn wounds
- More straightforward, efficacious, and cost-effective alternatives are needed.

Autologous blood clots (ABCs)

- Autologous blood clots (ABCs) may serve as an economical and effective scaffold for regenerative medicine applications.
- Our lab has previously shown ABCs to: 1) improve healing of surgical skin wounds and orthopedic defects, and 2) provide an effective vehicle for sustained delivery of antibiotics to a local wound site.
- Therefore, we investigated the effect of ABCs (both alone and conjugated with pharmaceuticals) on healing of partial-thickness thermal burns in a rat model.

METHODS



RESULTS

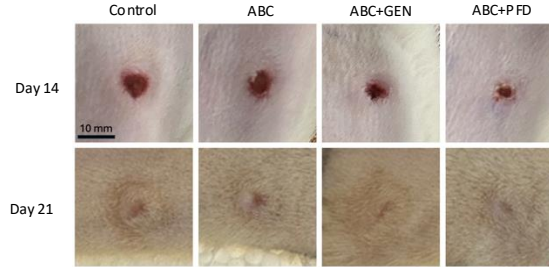


Figure 1. Representative photographs of burn wounds treated with control gel, ABC, ABC+GEN, and ABC+PFD 14- and 21-days post-burn. n=4.

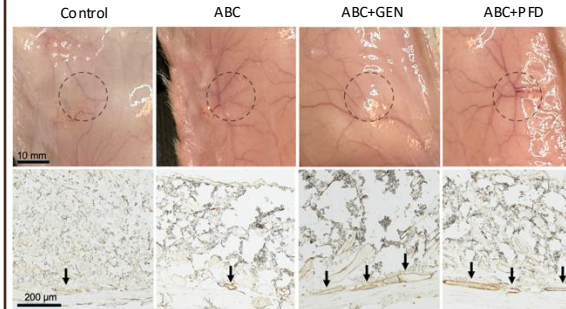


Figure 2. Treatment with ABC+GEN and ABC+PFD enhances angiogenesis following deep, partial-thickness burn wounds at 21-days post-burn. A) grossly, ABC+GEN- and ABC+PFD-treated groups displayed superior angiogenesis in regions underlying the burn wounds (dashed circle). B) immunohistochemistry with anti-smooth muscle actin identified more blood vessels (arrows) in ABC+GEN- and ABC+PFD-treated groups. Representative of n=4.

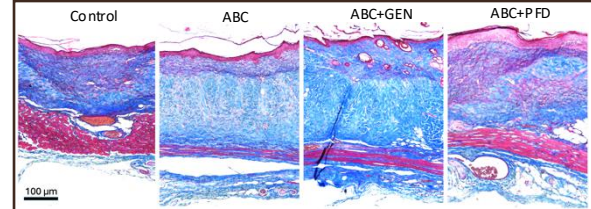


Figure 3. Histology of control-, ABC-, ABC+GEN-, and ABC+PFD-treated burn wounds at day 21. Stained with Masson's Trichrome. Representative of n=4

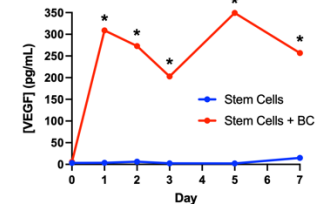


Figure 4. Mesenchymal stem cells cultured with BC release superior levels of VEGF, as compared to stem cells alone. n = 4; * indicates p ≤ 0.005.

CONCLUSION

- ABCs are an economical, quick, and easy to prepare biomaterial for regenerative medicine.
- ABCs may prove an effective treatment for deep, partial-thickness thermal burn wounds, as they: 1) hasten wound closure, 2) reduce fibrosis, and 3) promote angiogenesis.
- Ongoing research focuses on assessing impacts at additional timepoints

REFERENCES

- Deitch EA, Wheelahan TM, Rose MP, Clothier J, Cotter J. Hypertrophic burn scars: analysis of variables. *J Trauma*. Richter et al. (2023). Autologous blood clots: a natural biomaterial for wound healing. *Frontiers in Materials*. Wasiak J, Cleland H, Campbell F. Dressings for superficial and partial thickness burns. *Cochrane Database Syst Rev*.